

Vitamin D Deficiency and Chronic Low Back Pain in Saudi Arabia

Saud Al Faraj, MD*, and Khalaf Al Mutairi, MD†

Study Design. Initial assessment involved 360 patients (90% women and 10% men) attending spinal and internal medicine clinics over a 6-year period who had experienced low back pain that had no obvious cause for more than 6 months. The patients ranged in age from 15 to 52 years.

Objectives. To investigate the contribution of vitamin D deficiency as a cause for idiopathic chronic low back pain, to find a simple and sensitive test for screening patients with low back pain for vitamin D deficiency, and to determine the correlation between the vitamin deficiency and pain.

Methods. A biochemical assay of serum calcium, phosphate, alkaline phosphatase, and 25-hydroxy vitamin D level was performed before and after treatment with vitamin D supplements.

Results. Findings showed that 83% of the study patients (n = 299) had an abnormally low level of vitamin D before treatment with vitamin D supplements. After treatment, clinical improvement in symptoms was seen in all the groups that had a low level of vitamin D, and in 95% of all the patients (n = 341).

Conclusions. Vitamin D deficiency is a major contributor to chronic low back pain in areas where vitamin D deficiency is endemic. Screening for vitamin D deficiency and treatment with supplements should be mandatory in this setting. Measurement of serum 25-OH cholecalciferol is sensitive and specific for detection of vitamin D deficiency, and hence for presumed osteomalacia in patients with chronic low back pain. [Key words: chronic low back pain, 25-OH vitamin D level, oral vitamin D therapy, serum] *Spine* 2003;28:177-179

Although Saudi Arabia enjoys a sunny climate throughout the year, direct exposure to sunlight by the local population is hardly practical. This is partly because of the excessive heat, which makes sunbathing a risk for heat disorders, and partly attributable to cultural reasons whereby Muslim communities, especially the women, tend to avoid body exposure. This adds an extra burden to the calcium balance for the female population, together with that of pregnancy and lactation, throughout their reproductive life. Accordingly, vitamin D deficiency

is expected to be a major problem in such a community, especially for women during their years of reproduction.^{3,5,10}

The clinical manifestation of vitamin D deficiency is protean, and lower back pain alone is a well-recognized presentation of the disease.³⁻⁵ This study was conducted to assess the contribution of vitamin D deficiency to lower back pain, a major symptom in the presentation of patients.

Methods

Patients seen initially were assessed clinically for pain and the presence or absence of neurologic manifestation using plain radiograph of the lumbosacral spine, complete blood count, and ESR. Patients who had a mechanical cause for the back pain were excluded from the study. Both CT scanning and MRI of lower spine were performed to exclude disc prolapse, spinal stenosis, and degenerative disease of the spine. These patients were labeled as having idiopathic low back pain after the aforementioned assessment. Patients with clinical features suggestive of neurologic involvement were excluded.

Patients with renal impairment or chronic liver disease also were excluded from the study. Venous sampling was done for serum calcium, phosphate, alkaline phosphatase, and 25-hydroxy vitamin D3. The latter was measured by radioimmunoassay (RIA) using kits supplied by Dia Sorin (Minnesota, USA). The normal range accepted in our laboratory was 22.5 to 93.8 nmol/L. Oral therapy with 25-OH cholecalciferol using a dosage of 5000 to 10,000 U/day was commenced for all patients after venous blood sampling. Patients whose weight was less than 50 kg were given 5000 U/day, and those with weight exceeding 50 kg were given 10,000 U/day. Three months after vitamin D therapy had begun, measurements of all the aforementioned parameters were repeated, with clinical assessment of pain.

Results

The results of this study are presented in Table 11 and Figure 1. From a total of 360 patients, 299 (83%) (24 men and 275 women)(83%) were found to have a low serum level of 25-OH vitamin D3. These patients were further subdivided into groups with mild (15-22.4 nmol/L), moderate (10-14.9 nmol/L), and severe deficiency (<10 nmol/L). Serum calcium phosphate and alkaline phosphatase both were at normal levels in all 360 patients. There was no measurement of 24-hour urinary excretion because of technical difficulties in clarifying instructions to patients. The measurements of serum calcium, phosphate, alkaline phosphatase, and 25-OH vitamin D3 all were repeated after 3 months of therapy with 25-OH cholecalciferol 5000-10000 U/day.

From the Departments of *Medicine and †Spinal Surgery, Riyadh Armed Forces Hospital, Riyadh, Saudi Arabia.

Acknowledgment date: December 12, 2001. First revision date: April 16, 2002.

Acceptance date: June 3, 2002.

Device status/drug statement: The submitted manuscript does not contain information about medical devices or drugs.

Conflict of interest: No funds were received in support of this work. No benefits in any form have been or will be received from a commercial party related directly or indirectly to the subject of this article.

Address reprint requests to Dr. Saud Al Faraj, Department of Medicine, Riyadh Armed Forces Hospital, Saudi Arabia. E-mail: alfaraj@yahoo.com.

Table 1. Vitamin D Levels at Presentation

	25-OH Vitamin D3 Level (nmol/L)	Number of Patients	
		Females	Males
Normal	22.5–93.8	49	12
Mild	15–22.4	101	20
Moderate	10–14.9	102	4
Severe deficiency	<10	72	—

All 360 patients normalized their serum level of vitamin D after vitamin therapy, and there were no episodes of hypercalcemia. However, only 341 patients (95%) reported disappearance of low back pain after vitamin D therapy, all the patients with low serum 25-OH vitamin D3 and 42 of patients whose level of 25-OH vitamin D3 was normal initially (Table 2 and Figure 2).

■ Discussion

Osteomalacia is a common metabolic disease characterized by defective bone mineralization, as seen histologically, and the clinical infestations are protean.^{6,7} Vitamin D deficiency, whether nutritional or caused by lack of UV exposure or malabsorption, is a major cause of osteomalacia. Chronic low back pain is an extremely common problem in general practice, internal medicine, and spinal clinics, where the condition often is labeled idiopathic. Chronic low back pain has been documented well as a presenting symptom of osteomalacia,⁷ but to the best of the authors' knowledge, no studies have been conducted to analyze the contribution of vitamin D deficiency to the etiology of chronic low back pain as a presenting symptom in a large population wherein vitamin D deficiency is endemic.

Diagnosing vitamin D deficiency or fully blown osteomalacia on clinical grounds is not feasible because pre-

Table 2. Symptomatic Response to Oral Therapy with Vitamin D3 in the Two Groups of Low and Normal Vitamin D3—Serum Levels

	Level of 25-OH Vitamin D3		
	Low	Normal	Total
Total number of patients	299	61	360
Total numbers of responders to vitamin D3 oral therapy	299	42	341
Percentage of responders	100%	68.85%	94.72%

sentation can mimic a lot of conditions.^{1,7} Most radiologic signs of osteomalacia are not specific to vitamin D deficiency, and no definite diagnosis can be made accordingly.⁷ Isotope imaging and bone mineral density measurements are not easily accessible tests and not specific for osteomalacia.² Secondary hyperparathyroidism is common with vitamin D deficiency. Although elevated parathormone is not uncommon in these patients, it is not directly diagnostic of the condition. Furthermore, primary hyperparathyroidism may coexist with vitamin D deficiency, and this may be unmasked after treatment of the deficiency.^{4,9} Measurement of 24-hour urinary excretion of calcium is a simple and cheap test, but it may be difficult to convey the information to ambulatory patients and to ensure their strict compliance.

The result of observations in the community tested for this study showed a high prevalence of vitamin D deficiency in patients presenting initially and predominantly with low back pain. Furthermore, there is a remarkable clinical and biochemical response to oral therapy with vitamin D. The most obvious recommendation for areas with endemic vitamin D deficiency is to screen all pa-

Figure 1. 25-OH Vitamin D3 levels in patient group (n=360), with levels subdivided into the groups: normal (22.5–93.8 nmol/L), mild deficiency (15–22.4 nmol/L), moderate deficiency (10–14.9 nmol/L), and severe deficiency (<10 nmol/L).

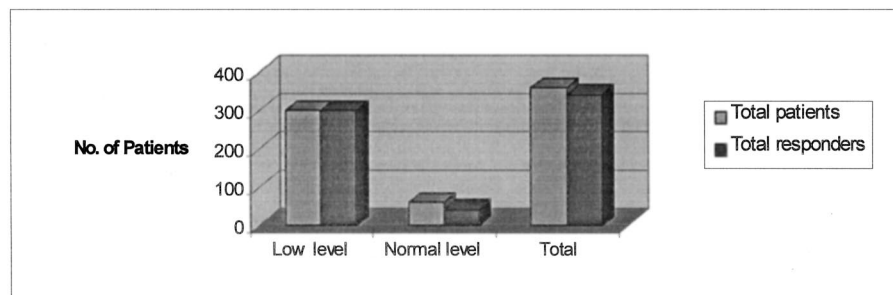
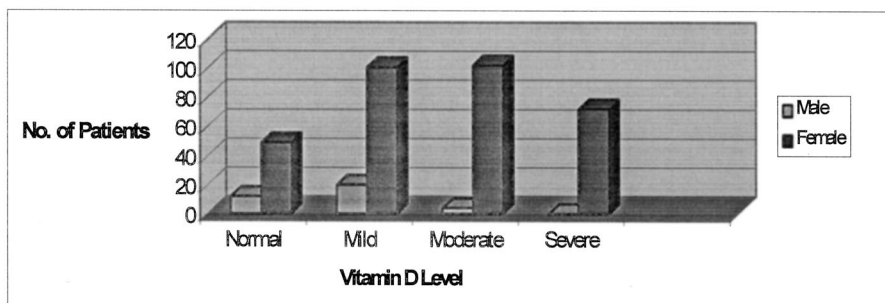


Figure 2. Ninety-five percent of patients reported a cessation of low back pain after vitamin therapy.

tients with low back pain for vitamin D deficiency by measurement of serum 25-OH cholecalciferol.⁸

■ Key Points

- Chronic idiopathic low back pain is commonly caused by vitamin D deficiency in Saudi Arabia, especially among female patients.
- Patient response to oral vitamin D therapy is quite rewarding.
- Screening for vitamin D deficiency should be performed for all patients with chronic low back pain.

References

1. Dorst AJ, Ringe JD. Severe osteomalacia in endemic sprue: An important differential diagnosis in osteoporosis. *Fortschr Med* 1998;116:42–5.
2. El-Desouki M, Al-Jurayyan N. Bone mineral density and bone scintigraphy in children and adolescents with osteomalacia. *Eur J Nucl Med* 1997;24:202–5.
3. Francis RM, Selby PL. Osteomalacia. *Baillieres Clin Endocrinol Metab* 1997;11:145–63.
4. Gannoge MH, Abikaram G, Nasr F, et al. Osteomalacia secondary to celiac disease, primary hyperparathyroidism, and Graves disease. *Am J Med Sci* 1998;315:36–9.
5. Gullu S, Erdogan MF, Uysal AR, et al. A potential risk for osteomalacia due to sociocultural lifestyle in Turkish women. *Endocr J* 1998;45:675:8.
6. Reginato AJ. Musculoskeletal manifestations of osteomalacia. *Rev Rhum France Ed* 1997;64(6 Suppl):1075–135.
7. Reginato AJ, Falasca GF, Pappu R, et al. Musculoskeletal manifestations of osteomalacia: Report of 26 cases and literature review. *Semin Arthritis Rheum* 199;28:287–304.
8. Renton P. Radiology of rickets, osteomalacia, and hyperparathyroidism. *Hospital Med* 1998;59:399–403.
9. Taylor AV, Wise PH. Treatment of vitamin D deficient osteomalacia may unmask autonomous hyperparathyroidism. *Postgrad Med J (Br)* 1997;73:813–5.
10. Wauters IM, van Soesbergen RM. Diseases caused by lack of sunlight: Rickets and osteomalacia. *Ned Tijdschr Geneesk* 1999;143:593–7.